

EP 343: A Rare and Interesting Case of Angiomyxoma of Genital Tract

Dr Miloni More, Dr Monika Gupta, Dr Saritha Shamsunder
Vardhman Mahavir Medical College, Safdarjung Hospital

INTRODUCTION

- Angiomyxoma is a rare mesenchymal tumour, typically arising from the connective tissue of the lower pelvis or perineum.
- It has a propensity for local recurrence and hence is termed 'aggressive'.
- Less than 10 such cases have been reported in literature in India.

CASE REPORT

- A 40-year-old multiparous female presented to the out-patient department with complaints of polymenorrhea and pain abdomen for one month.
- On examination, a polypoid mass was observed arising from the posterior lip of cervix.
- Excision of polyp planned and done.
- On histopathological analysis of the mass, a well circumscribed neoplasm comprising of satellite cells embedded in myxoid stroma was seen with interspersed chicken wire blood vessels, diagnosed as Angiomyxoma.

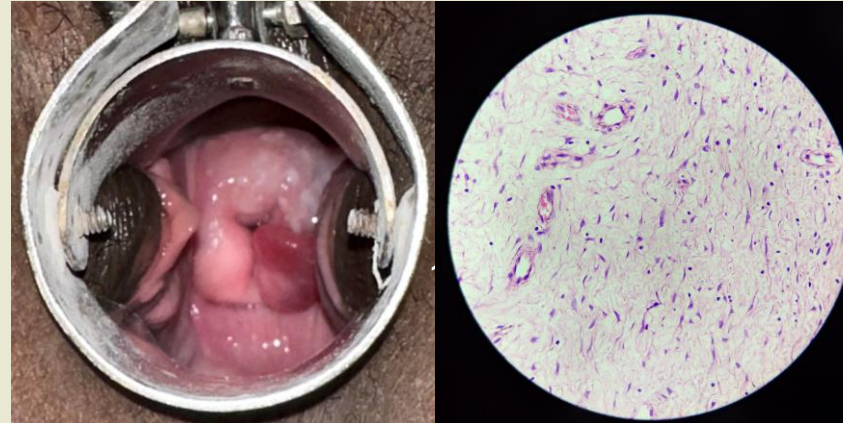


Fig.1: Polyp seen on PS examination

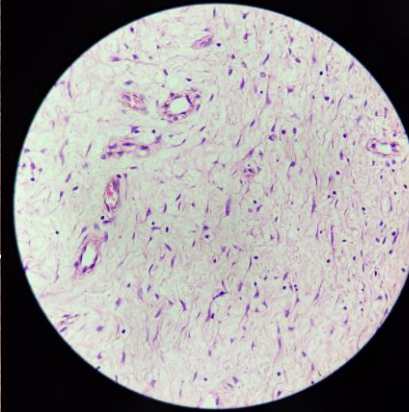


Fig.2: Tumour on 40x (high power) magnification

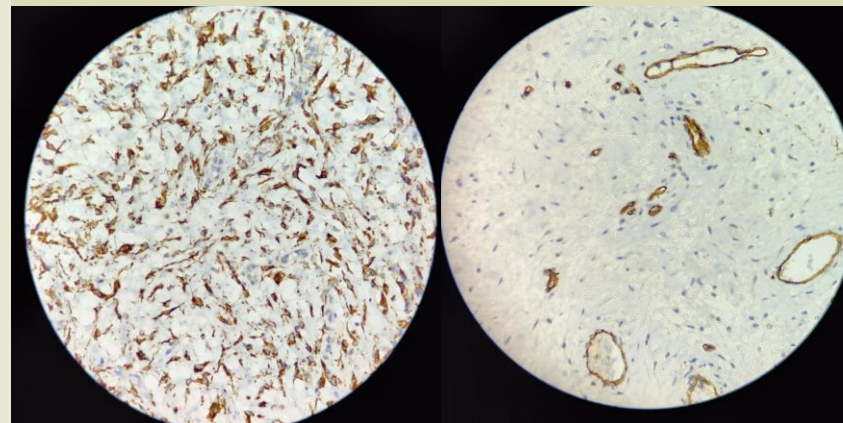


Fig.3 & 4: Immunohistochemistry

DISCUSSION

- The tumour was differentiated from other myxoid tumours by its unique features, including the striking vascular component.
- On immunohistochemistry, tumour cells were found to be positive for Desmin and ER, vessels highlighted by CD34 and SMA.
- Complete excision is the treatment of choice due to the potential for local recurrence and its aggressive nature.
- Other treatment options include hormonal manipulation such as tamoxifen, GnRH analogues, radiotherapy and arterial embolization.
- Recurrence rate varies from 36-70%.

CONCLUSION

- Angiomyxoma, though rare, can present as a cervical polyp, highlighting how rare disease can have trivial presentations.
- Long-term follow-up is essential and this patient is currently doing well.

REFERENCES

1. Bothale KA, Mahore SD, Joshi AM. A rare presentation of aggressive angiomyxoma as a cervical polyp. J Basic Clin Reprod Sci 2012; 1:65-7.
2. Dash B, Rath S, Rekhi B, Mittal N, Kulkarni R, et al. Vulvo-vaginal stromal tumours - Case series of a rare entity from an oncology centre in India. Gynecol Oncol Rep. 2024 Jul 28;55:101464.